

eConsults

Explore a collection of eConsult responses
across multiple specialty areas





eConsults

Explore a collection of eConsult responses across multiple specialty areas

Arista|MD

eConsults by specialty

Hematology	3
Hepatology	4
Allergy and Immunology	5
Dermatology	6
Nephrology	7
Child Neurology	8
Orthopedic Surgery	9
Pediatric Pulmonology	11
Pediatric Cardiology	12
Pediatric Dermatology	13
Pediatric Hematology/Oncology	15
Psychiatry	16
Wound Care	17

All patient, provider, and specialist details have been removed to de-identify these eConsults.

Hematology

CHIEF COMPLAINT

Thrombophilia/ Venous Thromboembolism (VTE)

DETAILS/COMMENTS TO SPECIALIST

65 yo female with h/o of renal and uterine cancer with nephrectomy and hysterectomy and currently in remission. April 2019 pt found to have DVT. Was started on Xarelto. Pt reports h/o blood clots prior to this incident.

MAIN QUESTION

Please evaluate and advise on discontinuation of Xarelto

Response from AristaMD eConsult Specialist

SUMMARY

Treatment options available at the primary care level.

DETAILS

My consult: Thank you for this Hematology eConsult for this patient with multiple medical problems and LLE DVT in April 2019. I will summarize as follows: 1) H/O RCCA S/P lap right nephrectomy January 2019. 2) H/O uterine cancer S/P surgery October 2018. 3) Morbid obesity S/P gastric bypass surgery in March 2019. 4) LLE DVT from common femoral vein to below the knee by Doppler on 4/15/19 -- provoked from post-op nephrectomy and bariatric surgery? On Xarelto since April 2019 w/o bleeding complications. 5) Apparent history of "previous DVTs" in the past -- no details. 6) No noted H/O FH of VTE. 7) Multiple other medical problems including extensive cardiac risk factors. 8) No tobacco use. 9) No CBC provided.

By history this sounds like a provoked DVT in the setting of sedentary lifestyle and 2 surgeries in early 2019. However, the previous H/O "DVTs" is worrisome -- where were they? Provoked vs unprovoked? Is the current LLE DVT in the same leg and venous distribution as any previous leg DVT? Any H/O PEs? Any FH of VTEs or recurrent miscarriages?

At this point I recommend the following:

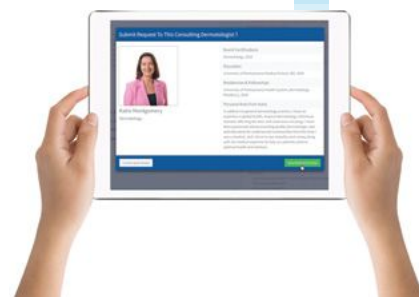1) Check Prothrombin 20210 and Factor 5 Leiden gene tests now. 2) Check Anticardiolipin antibody panel now. 3) Check Beta-2-glycoprotein antibody panel now. 4) Continue Xarelto for a minimum of 6 months. 5) Recheck Left Leg Doppler US at the end of 6 months before stopping the Xarelto -- if there is significant persistent thrombus, continue anticoagulation. 6) If any restaging scans reveal recurrent and/or metastatic disease from patient's 2 cancers, patient would fit criteria for lifelong anticoagulation. 7) If the patient is able to come off of anticoagulation based on #3 and #4 above, then I would wait 4-6 weeks after Xarelto discontinuation and then check the following: --Protein C and Protein S activity level. --Antithrombin 3 activity level. --Lupus anticoagulant.

For the patient:

1) Obtain more history regarding the prior VTEs. 2) Any FH of VTEs? 3) Aggressive cardiovascular risk factor modification -- obesity, DM, HTN, HLD, sedentary lifestyle.

Allow me to review the results of the above-recommended studies and we will proceed thereafter as clinically indicated. Thank you for allowing me to participate in the care of this patient.

Have a great night.



Hepatology

CHIEF COMPLAINT

Elevated liver function tests

DETAILS/COMMENTS TO SPECIALIST

A 49 yo Hispanic/Latina American female with DM type 2 who has had chronically elevated alkaline phosphatase. Patient reports that this has been ongoing for the past few years. Serum calcium also elevated, but patient denies taking supplements. Please see attached labs and visit note.

MAIN QUESTION

Please advise on how to proceed with reasonable fashion for pt with NO insurance and cannot afford expensive workup.

Response from AristaMD eConsult Specialist

SUMMARY

Patient can be treated at primary care level with specialist instruction.

DETAILS

Recommended diagnostics: Thank you for asking me to provide my recommendation regarding this patient. At present, given her metabolic syndrome, increased body weight, insulin resistance, hypercholesterolemia and hyperlipidemia, the most likely diagnosis is Non-alcoholic fatty liver disease. In this setting, alk phos, GGT, AST and ALT may be elevated in a pattern such as that seen in this patient. You have checked a GGT which shows that at least some of the alk phos is liver derived; however, the bone component of the alk phos is also elevated. It might be valuable to check an Anti-mitochondrial antibody (AMA) to rule out PBC. I recognize that the patient has limited medical coverage, however, a baseline ultrasound would be valuable to assess for any biliary, gall bladder, or liver abnormalities. Please see my suggestions below.

Recommended actions: 1) patient needs improved diabetes control, a low glycemic or Mediterranean diet, weight loss and she should start an exercise program. If her liver tests improve with this regimen, a more extensive evaluation of her liver condition is not indicated. 2) there is no contraindication to start a statin with careful attention to her liver enzymes. 3) she has been exposed to HAV but she should be vaccinated for HBV. 4) If her liver enzymes do not improve with weight loss, diet, exercise, she may need more advanced liver imaging such as an MRI/MRCP.

Recommended patient actions: Patient needs improved diabetes control, HgA1C is > 6, she should be attentive to a low glycemic diet, start an exercise program, she can start a statin.

Recommended follow up: See above.



Allergy and Immunology

CHIEF COMPLAINT

Allergy

DETAILS/COMMENTS TO SPECIALIST

A 60 yo female with h/o chronic cough. Also has h/o HTN (lisinopril increased from 2.5 mg, then 5 mg, now 10 mg in February) and type 2 diabetes. In 2016 was on Zyrtec, then switched to loratadine; then on 4/22/2019 switched back to Zyrtec. Has not had relief of nasal congestion nor cough.

MAIN QUESTION

Please evaluate and advise on further workup and treatment. Thank you.

Response from AristaMD eConsult Specialist

SUMMARY

Patient can be treated at primary care level with specialist instruction.

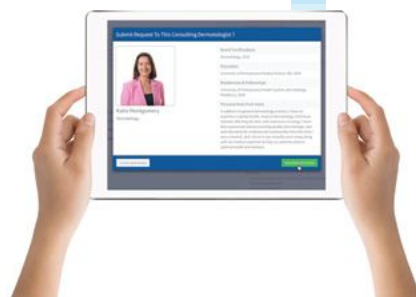DETAILS

Recommended diagnostics: CBC with differential, limited inhalant allergen panel (for IgE antibody against regional environmental allergens, including dust mites, cat, dog, molds, and pollens [tree/grass/weed]).

Recommended actions: Thank you for asking my opinion on this 60 yo Cambodian female patient with a chronic cough and suspicion of environmental allergies. Relevant background provided includes history of a "hacking cough," use of an ACE inhibitor for hypertension, use of oral antihistamine and fluticasone spray for clinical diagnosis of environmental allergies, lifelong non-smoker, normal respiratory tract exam, negative TB testing, very low vitamin D (now on supplementation), question of cardiomegaly (referred to cardiology), and denies wheezing, shortness of breath, irregular heartbeats, or peripheral edema. The differential would most commonly include environmental allergies, chronic sinusitis, asthma, or GERD/LPR, and in this patient's case the cardiac concern of cardiomegaly and use of ACE inhibitor. The suggested initial approach would include: additional history- in regards to suspected environmental allergies (i.e. h/o sneezing, itching, rhinorrhea, presence/absence of nasal congestion/mouth breathing/decreased sense of smell, concurrent ocular itching, redness and watering), have seasonally increased symptoms in spring/summer been noted, and are there specific triggers identified that reinforce suspicion of allergy (i.e. from cats, dogs, grasses). Would also inquire as to the consistency of the cough as to dry or productive, daytime and nighttime presence, how often post-nasal drainage is noted, if there is phlegm in the morning upon awakening, frequency of throat clearing and frequency of heartburn symptoms. labs- as suggested above. Would also review report on recent CXR presumed to be the basis of concern for cardiomegaly, to verify there are no incidental findings. If no recent CXR, would obtain PA/lateral. Since the patient has been referred to cardiology, I would also inquire as to a change in antihypertensive from the ACE inhibitor to another medication class, as chronic cough can develop even after many years of uneventful ACE inhibitor use, even on a stable dose. If the ACE inhibitor is the cause, it can be a few months before the cough resolves entirely. If the patients labs show significant environmental allergy, and fluticasone spray and antihistamine were used very consistently, then referral to allergy to discuss desensitization/immunotherapy would be a strong consideration. If the regional allergen panel is unremarkable, and there has been no response to a change from the ACE inhibitor, would then review CBC w/diff, and if without eosinophilia, would pursue either chronic sinusitis or LPR as most likely cause of the cough over asthma. If nasal congestion and increased phlegm in the morning, after being supine for the night, I would treat with three weeks of antibiotic (typically amox-clav). If minimal upper airway symptoms, other than perception of post-nasal drainage, would try a PPI trial first. If the cough is still present after the above, I would refer to allergy for further assessment, especially if eosinophilia is noted on the CBC w/diff. This lab finding could also raise additional questions in regards to infectious, pulmonary, rheumatologic concerns, depending on when the patient arrived in the US from Cambodia. Obtain history on seasonal sneezing, reflux symptoms.

Recommended patient actions: Take medications consistently, so the provider will know whether or not they are effective. Obtain lab tests in a timely manner, when requested to do so.

Recommended follow up: I would be happy to answer additional questions now, and in further followup.



Dermatology

CHIEF COMPLAINT

Rash

DETAILS/COMMENTS TO SPECIALIST

Patient with rash that started as red, itchy, and dry—using moisturizer/lotions. Tried calamine, but not helping, and now worsening. Located on arms/legs/chest and lower abd, not upper abd. Thickening near elbows and outer legs. Also noted around pinnas b/l. No hx of eczema/asthma. No hx of seasonal allergies. Not taking meds regularly, nor has been on any new medications, and no new fragrances/detergents/soaps.

MAIN QUESTION

Please advise

Response from AristaMD eConsult Specialist

SUMMARY

Patient can be treated at primary care level with specialist instruction.

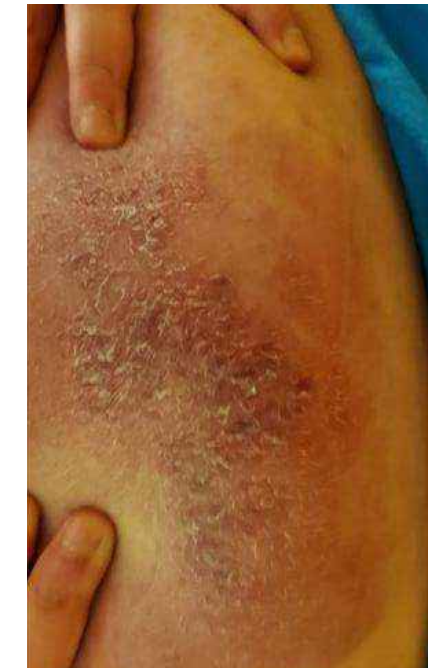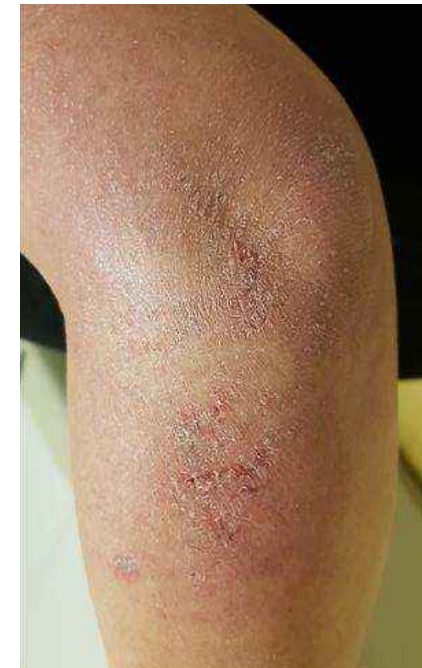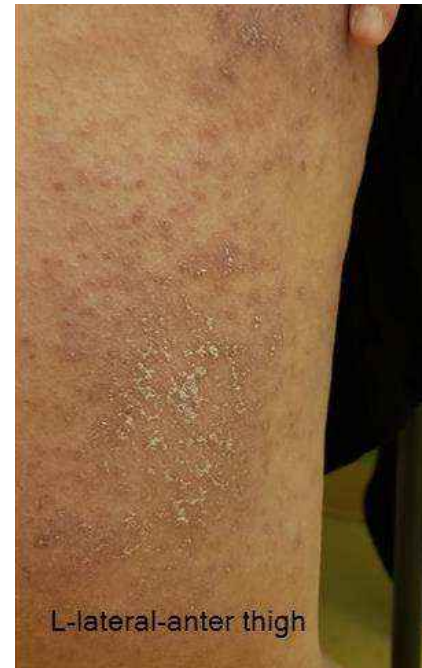DETAILS

Recommended diagnostics: A progressive dermatitis/eczema such as this is usually triggered by an allergen or irritant which is likely gone and unlikely to be remembered by the patient. If we can achieve adequate remission, no further investigation may be necessary. Eczema, once established, is auto inflammatory with characteristic increasing intensity, pruritus, and spread, even to non contiguous areas(I'd reaction). Aggressive intervention can result in remission. The prednisone 20 may help some, but usually higher doses are required with an individualized taper, so I recommend the following.

Recommended actions: Suggestions: Kenalog 40 mg IM. Doxycycline 100mg bid for several weeks, both for the anti inflammatory effect and because the skin is colonized. Cleanse with CLn (sodium hypochlorite) body wash or hypochlorous acid (inexpensive/Amazon), bath or shower. The triamcinalone cream can be used for several weeks at a time with relative impunity, but should not be used on the face, where hydrocortisone 1% should be effective enough for short periods. The kenalog may need to be repeated in 3 to 4 weeks. Ammonium lactate (eg Amlactin) lotion is an effective, steroid enhancing and protective moisturizer, but can sting on inflamed skin.

Recommended patient actions: We will try to get this into remission and keep it there with a treatment "program."

Recommended follow up: Please let me know if you have any questions. If you would prefer to employ prednisone, I recommend a tapered course that is usually something like: 60x3days, 40x4 days, 20x6d, 10x6. However, it is frequently necessary to individualize further, and adjustments are frequently necessary. I have found IM kenalog more effective, easier to use and safer. If you would like more guidance, please just let me know.



Nephrology

CHIEF COMPLAINT

Other kidney cyst

DETAILS/COMMENTS TO SPECIALIST

Follow up Nephrology eConsult with Dr. G for 30 yo female for abnormal Renal imaging. 1) Follow up abdominal CT, kidney mass protocol - "shown bilateral benign - appearing renal cysts are present" (compared to a renal ultrasound - a 1 cm complex cyst is demonstrated in the inferior pole. Findings suggesting medullary sponge kidney. Thin cortex.". 2) Normal high serum calcium 10.2 (N8.6-10.2) and ionized calcium= 5.6 (N 4.8-5.6) with normal iPTH = 46. (N14-64) 3) random urine calcium = 22.4 (normal value is not established) 4) Normal uric acid = 3.8 A kidney stone (not sure of size) noted to the right cortex (awaiting addendum from the radiologist). Please see attached CT scan, Labs, Prior eConsult, and recent visit note. Thank you.

MAIN QUESTION

See questions regarding this patient:

- 1) How to best manage this patient?
- 2) Can we assume that the stone is likely calcium formation and treat as such?
- 3) Can the CT scan exclude the medullary sponge kidneys as suggested in the renal ultrasound?
- 4) Is random urine calcium considered normal?

Response from AristaMD eConsult Specialist

SUMMARY

Patient can be treated at primary care level with specialist instruction.

DETAILS

Recommended diagnostics: Once again, patients with Medullary sponge kidney usually have very good renal prognosis. However, it is associated with Nephrocalcinosis and increased chances of UTI. Here my answers to your questions: 1) How to best manage this patient? ==> See discussion and Ox recommendations 2) Can we assume that the stone is likely calcium formation and treat as such? ==> Most likely, yes, but see below 3) Can the CT scan exclude the medullary sponge kidneys as suggested in the renal ultrasound? ==> Not exactly. May need to discuss with Radiology interpretation of the CT in regard to the medullary sponge kidney. IVP may be considered to establish imaging diagnosis 4) Is random urine calcium considered normal? ==> NO! Needs full 24 hr urine for Creatinine, Calcium, citrate, oxalate and uric acid. Once it is clear which metabolic abnormality is responsible, more specific dietary and ? supplementation measures will need to be further discussed. I recommend to discuss with the Radiologist interpretation of the latest CT scan in regard to medullary sponge kidney. Possible use of IVP as well.

Recommended actions: Complete suggested testing. Consider discussion with the radiologist review interpretations of both CT and previously done UIS May benefit from Dietician evaluation.

Recommended patient actions: - 2 L fluid intake daily; - low Na (< 2000 ng/day); - prevalence of of non-animal protein intake; - Low oxalate diet; - watch for signs of UTI.

Recommended follow up: Next 2-3 mo with labs as outlined above.



Child Neurology

CHIEF COMPLAINT

Headache

DETAILS/COMMENTS TO SPECIALIST

Patient with near daily headaches, usually over occiput and radiates on left side of head forward, and throbbing. Headaches usually lasts all day; dark rooms help; usually associated with nausea and occasional vomiting. CT head at Murrieta ER without acute findings. Has only tried ibuprofen before.

MAIN QUESTION

Please advise on further work up or treatment options.

Response from AristaMD eConsult Specialist

SUMMARY

Patient can be treated at primary care level with specialist instruction.

DETAILS

Recommended diagnostics: Need to evaluate for signs of increased intracranial pressure. If the headache is worse with lying down or bending over, wakes the patient up at night, or if there is papilledema on fundoscopic exam then an MRI brain is indicated.

Recommended actions: If there are no signs of increased intracranial pressure as above then no need for further imaging. For symptomatic treatment, frequent headaches may be helped with a daily preventative medication - I often start with a combination of magnesium and riboflavin taken daily as this has been shown to be better than placebo and has minimal side effects. It will take 2-3 weeks to become effective. NSAIDs can be taken for symptomatic relief up to 3 or 4 days in a week but should not be taken every day.

Recommended patient actions: Headaches are exacerbated by poor sleep, dehydration, skipping meals, stress and anxiety. Certain foods may also trigger headaches such as caffeine, chocolate, and MSG.

Recommended follow up: Follow up 3-4 weeks after starting a daily preventative to check on efficacy. If there are any signs of increased intracranial pressure, as described above, further workup including imaging and possibly LP would be indicated.



SPECIALTY

Orthopedic Surgery

CHIEF COMPLAINT

Hip pain

DETAILS/COMMENTS TO SPECIALIST

c/o injured L hip at the gym 1 year ago using cane to ambulate doing leg curls on work out machine felt a burning sensation to L hip thought it was an injury the patient could recover from but no improvement in 1 year no redness, swelling no back pain no knee pain no numbness or tingling or weakness has not seen a doctor in 10 years. Visit note and x-ray report attached.

MAIN QUESTION

L hip pain, abnormal x-ray, does patient need face to face for eval or are there any conservative measures that need to be tried first, or should I get MRI first? Thank you so much.

Response from AristaMD eConsult Specialist

SUMMARY

Treatment options available at the primary care level.

DETAILS

My consult: This is an eConsult response for this patient. Patient has chronic left hip pain for 1 year, using a cane to ambulate.

Patient's x-ray reports indicate moderately advanced arthritic changes of the left hip.

Initial treatment would consist of a trial of NSAIDs and gentle physical therapy. NSAIDs will likely help.

Ultimately, if these measures fail, the patient will need to be seen by an orthopedic surgeon for evaluation for a hip replacement. Based on x-ray findings, and MRI will not add any additional information.



Orthopedic Surgery

CHIEF COMPLAINT

Other [?] finger concern

DETAILS/COMMENTS TO SPECIALIST

Disfigurement of finger after years of tight compression-any possibly treatment? See visit note, pictures at bottom.

MAIN QUESTION

Please advise

Response from AristaMD eConsult Specialist

SUMMARY

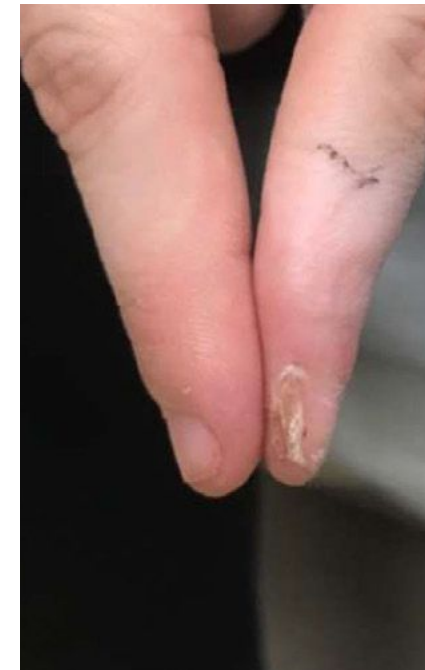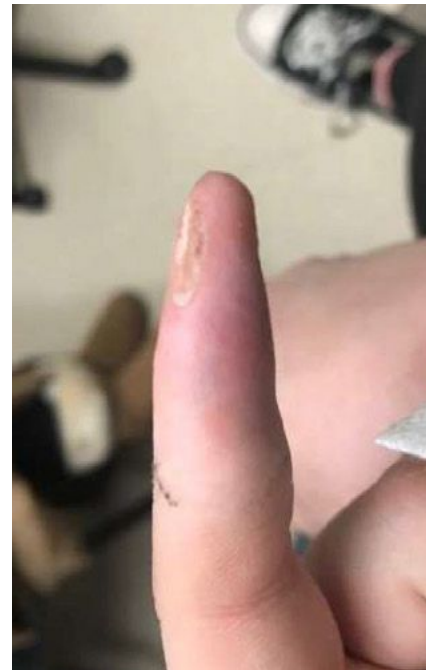Treatment options available at the primary care level.

DETAILS

My consult: This is a very unusual case. I agree that there is likely atrophy of the fat pad and soft tissues from years of compression. This may slightly improve with discontinuing the tight wrapping. If it does not improve, there is no surgery to restore the shape of the finger tip. Is the sensation normal?

However, the finger nail could be treated with partial resection if it doesn't improve with discontinuing the tight wrapping. It will take several months for the nail to grow out and see what happens. You could consider referral to a hand specialist in about 6-12 months after the finger has had adequate time to recover.

Because of the unusual nature of this case, it might be worthwhile to do a case report write up. I could not find anything in the literature on this topic.



Pediatric Pulmonology

CHIEF COMPLAINT

Chronic cough

DETAILS/COMMENTS TO SPECIALIST

A 5 yo female with cough for 2 months was recently seen in the ER for pneumonia. Currently on azithromycin and has also taken Augmentin to treat sinusitis. H/o non-allergic rhinitis and cough variant asthma. PFTs have been normal with FEV1 of 130%. Seen by ENT continuing ranitidine, started in December 2018, but only too it for 2 days.

MAIN QUESTION

Please evaluate and advise on further workup and treatment until patient can be seen face to face by Pulmonology. Thank you.

Response from AristaMD eConsult Specialist

SUMMARY

Patient should be seen, in-person, by a specialist.

DETAILS

Additional rationale: I definitely agree with a face-to-face Pulmonology consult for this patient. It sounds like she has a history of asthma and has been hammered with inhaled steroids both using budesonide as well as the Advair Diskus. It would never be my normal practice to use an Advair Diskus dry powder inhaler in a 5-year-old patient who really cannot effectively use this medication given the difficulty of using a dry powder inhaler and a 5-year-old. They have to keep their tongue out of the way, exhale all the way with her lips off of the discus, then inhale deeply enough to get the dry powder all the way into their lower airways. Typically, I save using the Advair Diskus for patient's age is 12 or older and would have this patient on the Advair 115 HFA inhaler with the AeroChamber spacer. I know she is seeing an allergist who is likely the one managing this medication, so this may have been the allergy recommendation to put her on a dry powder inhaler, it just seems unusual at 5 years of age. Additionally, I am not sure why they are continuing budesonide as well as the Advair instead of just stepping up the therapy to a higher dose inhaled steroid through the Advair. The cough certainly sounds interesting now being more wet and "phlegmy". The chest x-ray with perihilar peribronchial thickening certainly is normal in asthma, however they were noting the right side was worse than the left side on the report. Unfortunately, the films were not sent for me to look at myself so I could not offer opinion except from reviewing the report. I certainly agree with a pediatric pulmonology consult and if I were seeing this patient in my clinic, I would likely proceed with flexible bronchoscopy with bronchoalveolar lavage in order to obtain true lower airways cultures. Given the likelihood of a bronchoscopy to evaluate and obtain lower airway cultures, I would hold off on antibiotics right now and not recommend for giving her additional antibiotics so that hopefully they could proceed with the bronchoscopy soon and get good results of the bronchoalveolar lavage not tainted by recent antibiotic use. My recommendation would be to change her over now to highdose HFA inhaled ICS/LABA therapy with either Advair 230, Dulera 200, or Symbicort 160 all using 2 puffs twice a day with a spacer device to see if this makes any difference before the pulmonology visit. If that does not help, certainly they would want to proceed with a bronchoscopy and to get lower airways cultures. Additionally, please make sure there are no signs or symptoms of thrush since she was on the dry powder Advair Diskus and budesonide. If she has any signs of thrush, I would recommend for a 7-10-day course of Diflucan orally in case she is having candidiasis causing the significant cough. Additional consideration could also be given for habitual cough from airway inflammation from coughing or a tracheomalacia type cough. If she is having a deep barking hacking cough even if it is productive, it is possible she is irritating her airway significantly from this coughing and the irritated airway makes her want to keep coughing. The mention of chronic throat clearing in the notes does make this likely as these kids tend to have a significantly irritated airway that they are trying to essentially scratch/relieve by coughing or throat clearing but unfortunately this just causes more irritation which makes him want to cough more. Overall, long story short, I would try high dose combination ICS\LABA using an HFA inhaler and a spacer at 2 puffs twice a day while awaiting the pulmonology referral and likely bronchoscopy be done once seen by pulmonology. Hopefully this helps.



Pediatric Cardiology

CHIEF COMPLAINT

Chest pain

DETAILS/COMMENTS TO SPECIALIST

A 5 yo male with a nonspecific chest symptom. Please see note for details.

MAIN QUESTION

Please review EKG and note and provide additional recommendations for workup if needed

Response from AristaMD eConsult Specialist

SUMMARY

Patient can be treated at primary care level with specialist instruction.

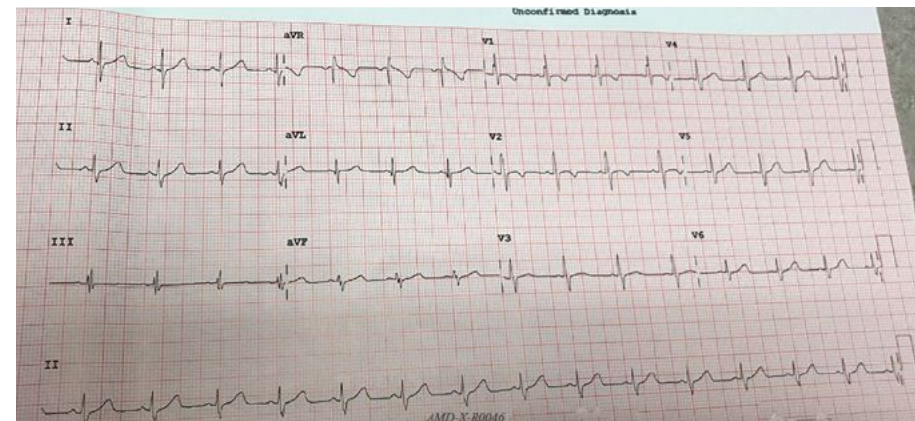
DETAILS

Recommended diagnostics: I reviewed the clinic encounter report dated 4.January-2019. Patient is a 5-year-old who reports a month long history of stinging sensation in the chest under a variety of circumstances (at rest and with physical activity). Episodes are self-limiting to within a minute or so. There are no associated symptoms. He has a past history of seasonal allergies and wheezing with upper respiratory illness. There is no mention of the health history for his mother or any siblings. His father has a history of childhood asthma. Findings on physical examination were unremarkable. I reviewed his ECG from the same encounter date. It shows sinus rhythm with right axis deviation along with notched QRS complexes in III, aVF, and V1 (otherwise normal QRS duration).

Recommended actions: Characteristics of this patient's chest pain do not appear cardiogenic, and specifically there is no evidence for pericarditis, myocarditis, or ventricular outflow tract obstruction on his combined physical examination and ECG findings. The notched QRS complexes in inferior and anterior leads, along with right axis deviation, can be seen in normal patients as well as those with a dilated right ventricle secondary to congenital heart disease unrelated chest pain such as atrial septal defect. Were this patient to have been seen in my office, I would conduct a transthoracic echocardiogram. This can be ordered by the primary care physician without cardiology consultation. If the echocardiogram is normal, no further cardiac evaluation/referral would be necessary.

Recommended patient actions: Your physician has conducted a thorough evaluation for the important cardiac causes of chest pain that can affect children. There is no evidence for a heart problem causing chest pain in his case. Unrelated to the question regarding chest pain, his ECG had a very minor difference from the average population at his age that may prompt your son's physician to order another test called echocardiogram (ultrasound of the heart). If that study is ordered and normal, no further cardiac evaluation is necessary.

Recommended follow up: Provide reassurance to patient's parents regarding the absence of findings in support of a cardiac cause of chest pain. In this age group, discriminating the exact meaning of "heart stinging" can be difficult, but the objective findings are unambiguously reassuring.



Pediatric Dermatology

CHIEF COMPLAINT

Other  herpes zoster

DETAILS/COMMENTS TO SPECIALIST

Onset: 5 days ago. The problem is worse. Location is armpits. The patient's mother describes the rash as itchy and papular. The symptoms are not aggravated by fever. Associated symptoms include pruritus. Pertinent negatives include cough, diarrhea, fever, pharyngitis and vomiting. Additional information: no change of soap or body spray, no sick contact.

MAIN QUESTION

12 y/o with rash under armpits, around the eye, possible herpes, please advise with diagnosis and treatment.

Response from AristaMD eConsult Specialist

SUMMARY

Patient can be treated at primary care level with specialist instruction.

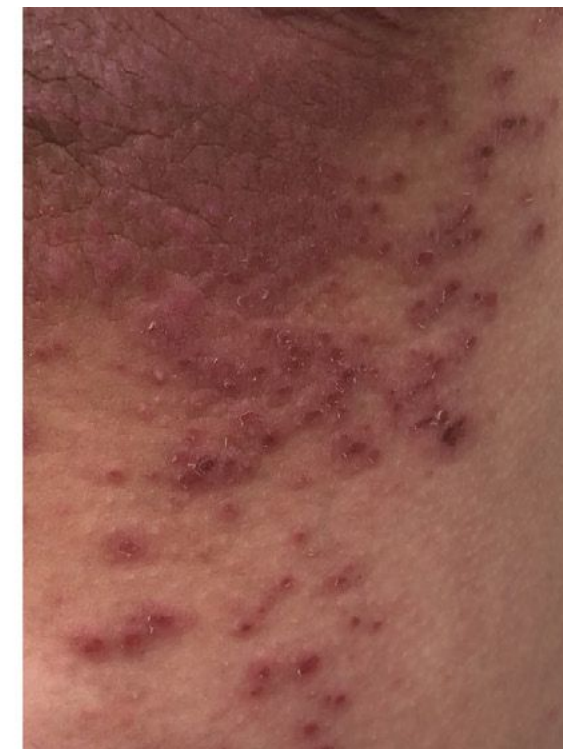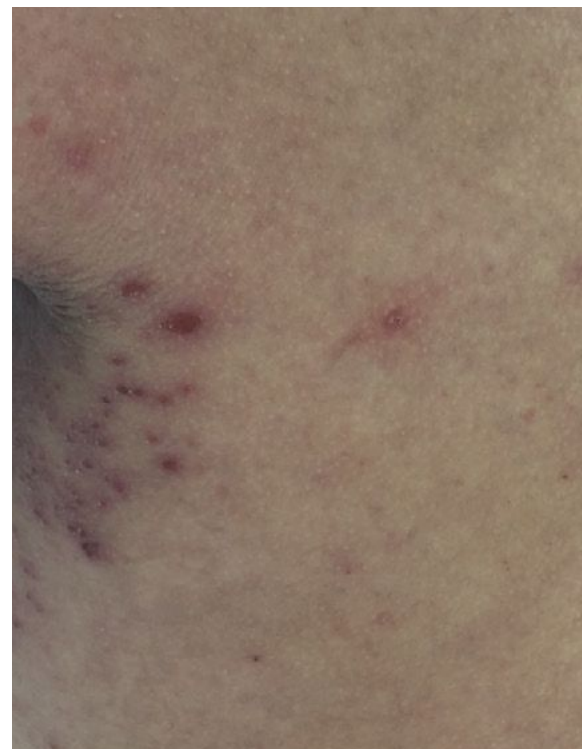DETAILS

Recommended diagnostics: Bacterial culture of affected area in left axilla. HSV culture and/or DFA/PCR of affected area in left axilla.

Recommended actions: Photos appear to show: -few small erythematous crusted papules at left back -many polymorphous superficial erosions with collarettes of scale at left axilla and trunk -few small erythematous crusted papules and superficial erosions on face -violaceous plaque with many surrounding erythematous papules and superficial erosions in left axilla -small violaceous plaque with surround erythematous papules and superficial erosions in right axilla. The morphology of the skin lesions does not appear to be consistent with cutaneous herpes. However, when HSV is suspected, I recommend a culture and/or DFA/PCR for confirmation. The erosions with collarettes of scale are more suggestive of bullous impetigo. I recommend a bacterial culture for confirmation and antibiotic sensitivities. It appears that the patient was treated with acyclovir and Keflex. I would follow up in a few days to see if the rash is improving. If there are persistent skin lesions, please re-consult with new photos as there may be an underlying process that became secondarily infected and is currently obscured by the secondary rash.

Recommended patient actions: Follow instructions that were given at visit.

Recommended follow up: 1 week for re-evaluation.



Pediatric Dermatology

CHIEF COMPLAINT

Other [?] Eczema

DETAILS/COMMENTS TO SPECIALIST

Please see attached pictures and visit note for further information.

MAIN QUESTION

10 yo male with hx of eczema, who has had a slowly enlarging itchy plaque on left shin for the past four years. Not responsive to typical eczema treatments. Please evaluate and offer guidance.

Response from AristaMD eConsult Specialist

SUMMARY

Treatment options available at the primary care level.

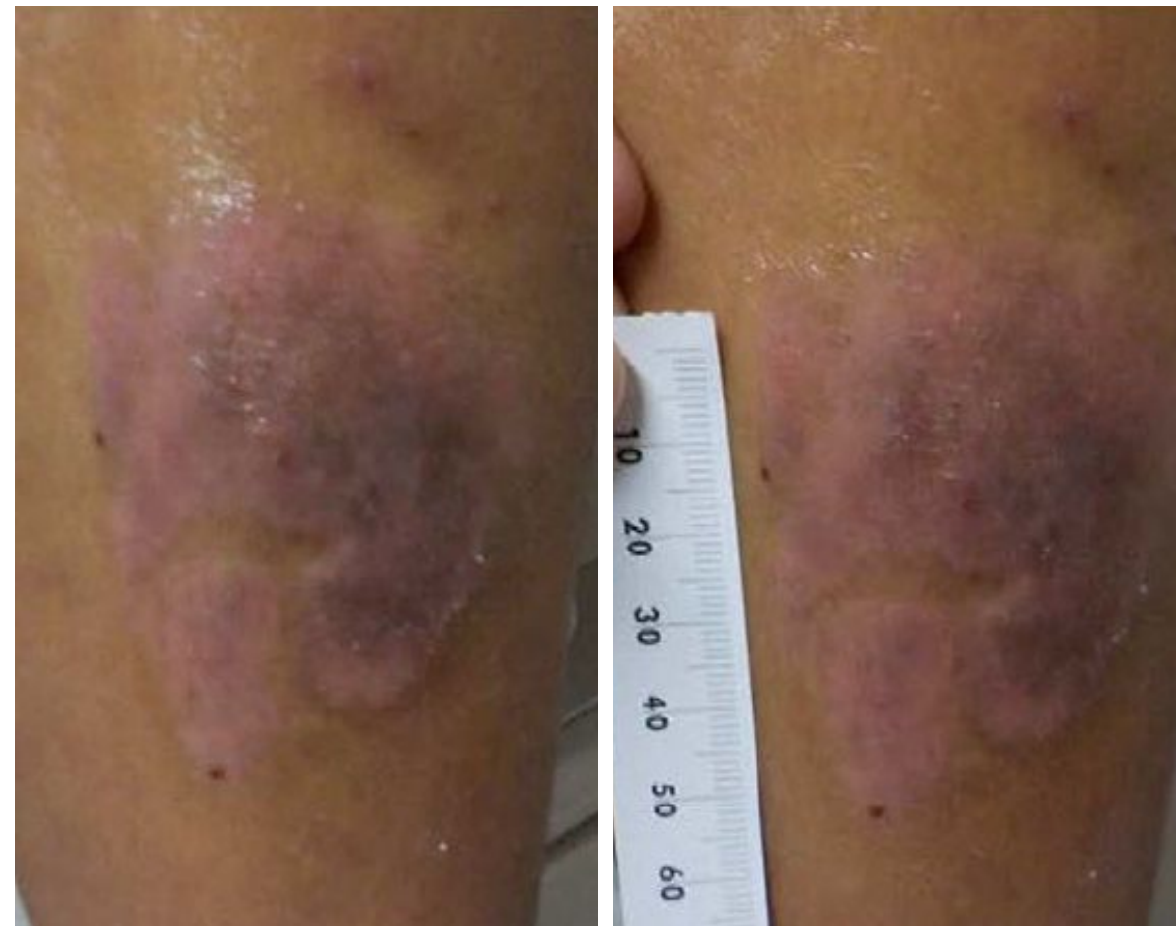DETAILS

Recommended diagnostics: None

Recommended actions: I favor lichen simplex chronicus from long term scratching and itching. If he hasn't tried a strong topical steroid, would recommend Clobetasol 0.05% ointment BID x 14 days to the affected area then re-evaluate. If improved, take 1 week off then repeat for 2 more weeks and use PRN for pruritus. If not improving, then would recommend biopsy to r/o other causes.

Recommended patient actions: Continue moisturizing with vaseline when not using steroids.

Recommended follow up: 2-4 weeks



Pediatric Hematology/ Oncology

CHIEF COMPLAINT

Other  splenic cyst

DETAILS/COMMENTS TO SPECIALIST

Patient being followed for horseshoe kidney with incidental finding of splenic cysts. Abdominal US completed and no cysts in any other organs but spleen with multiple cysts.

MAIN QUESTION

What follow up or work up is required for an asymptomatic child with multiple splenic cysts?

Response from AristaMD eConsult Specialist

SUMMARY

Patient can be treated at primary care level with specialist instruction.

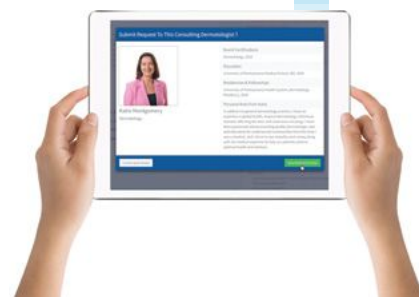
DETAILS

Recommended diagnostics: Splenic cysts are not something we commonly see in the pediatric population and is not something typically followed by pediatric hematology/oncology. I did find the following journal article regarding the management of splenic cysts: <https://www.ncbi.nlm.nih.gov/pubmed/29433866> J Surg Res. 2018 Mar;223:142-148. doi: 10.1016/j.jss.2017.09.036. Epub 2017 Nov 24. Management of nonparasitic splenic cysts in children. Hassoun J1, Ortega G2, Burkhalter LS3, Josephs S4, Qureshi FG5. **BACKGROUND:** The management of nonparasitic splenic cysts in children is unclear. Options include observation, cystectomy, partial or total splenectomy and percutaneous aspiration with and without sclerotherapy. The aim of this study is to assess the outcomes of these interventions at a children's hospital. **MATERIALS AND METHODS:** A retrospective review of patients aged < 18 y with splenic cysts over 7 y was performed. Demographics, mode of intervention, and outcome data were collected. **RESULTS:** Forty-two patients were identified and their initial management was as follows: 32 patients were observed and 10 underwent intervention (four aspiration and sclerotherapy and six resection). Age (y) was higher for intervention patients than observation patients (P = 0.004), as was the cyst size (P < 0.001). Incidental finding was the most common presentation in observation patients (n = 30; 94%) and abdominal pain for intervention groups: aspiration and sclerotherapy (n = 3; 75%) and resection (n = 5; 83%). Two patients failed observation and required aspiration and sclerotherapy due to persistence of symptoms or size increase. Median number of aspiration with and without sclerotherapy interventions was three (range 1-5). All six patients had persistence, with two requiring surgical resection due to symptomatic persistence. Surgical procedures included laparoscopic cystectomy (n = 3), laparoscopic partial (n = 2) or complete splenectomy (n = 1), and/or open splenectomy (n = 2). One laparoscopic cystectomy patient had persistence but the other two had no follow-up imaging. Partial and total splenectomy patients had no recurrence and/or persistence. **CONCLUSIONS:** Observation is an appropriate management strategy for small asymptomatic splenic cysts. Aspiration with and without sclerotherapy and laparoscopic cystectomy are associated with higher rates of recurrence; thus, partial splenectomy may provide the best balance of recurrence and spleen preservation. Based on this information and the patient's clinical history, he can likely be observed. The only children who received intervention are those who were symptomatic with abdominal pain and I did not see this complaint in his history. Based on this article, the patient should receive surveillance ultrasounds to monitor for cyst enlargement. There has only been a slight increase in the size of the cyst in the interval period, but if it continues to enlarge, it may necessitate removal.

Recommended actions: I would repeat the abdominal ultrasound in a year as the cyst only enlarged from 1 cm to 1.1 cm in the span of over a year. If the patient becomes symptomatic with pain, referral to a pediatric surgeon is likely warranted.

Recommended patient actions: Continue with regular follow-up and imaging as prescribed.

Recommended follow up: The patient should follow up and receive a repeat abdominal ultrasound in 1 year. The patient should return if any symptoms of abdominal pain appear.



Psychiatry

CHIEF COMPLAINT

Anxiety

DETAILS/COMMENTS TO SPECIALIST

A 62 yo female with h/o significant anxiety. She has many external stressor triggers. H/o Fibromyalgia and lupus. Has been on Cymbalta, Prozac, and Zoloft with adverse side effects of nightmares and insomnia. She is currently using lorazepam but states symptoms are not controlled.

MAIN QUESTION

Please advise on additional options for medication management.

Response from AristaMD eConsult Specialist

SUMMARY

Patient can be treated at primary care level with specialist instruction.

DETAILS

Recommended diagnostics: None.

Recommended actions: 62 y.o woman with h/o anxiety. Multiple stressors exacerbating anxiety. Unable to tolerate trials of cymbalta or ssri's. Currently treated only with benzodiazepine. This patients anxiety appears to be in the form of rumination about multiple stressors. An antidepressant medication is most likely to be of long term benefit. As patient has failed trials of cymbalta and ssri's and currently has some sleep problems. I would consider a trial of Remeron. Remeron 15 mg qhs can be started and dose may be increased in 15 mg increments every 4 weeks as tolerated. Sedation and increased appetite are the most common se's. Sodium levels should be monitored routinely in elderly patients as it can rarely cause hyponatremia. Pt will need to be educated on how antidepressants work as opposed to prn medications, such as her current benzodiazepine. She will need to understand that antidepressants may take up to 3 months to alleviate anxiety symptoms. Also, anxiety symptoms will improve primarily in form of decreased rumination. Later in treatment, physical symptoms of anxiety begin to improve. Benzodiazepine may be continued as prn, however strongly recommend switching to a long acting medication, such klonopin or valium. Long acting benzodiazepines have less risk of dependence.

Recommended patient actions: Strongly encourage pt to engage in therapy, specifically CBT, to help with anxiety symptoms. encourage general healthy lifestyle.

Recommended follow up: f/u in 4-6 weeks after med started or any dose adjustments check sodium level in 3 months, if Remeron is started.



Wound Care

CHIEF COMPLAINT

Wound care

DETAILS/COMMENTS TO SPECIALIST

A 54 yo male with left forearm abscess s/p I&D 4 days ago.

MAIN QUESTION

Please see note and pictures and given recommendations on wound care and if patient needs to be seen by a wound care clinic. Thank you!

Response from AristaMD eConsult Specialist

SUMMARY

Patient can be treated at primary care level with specialist instruction.

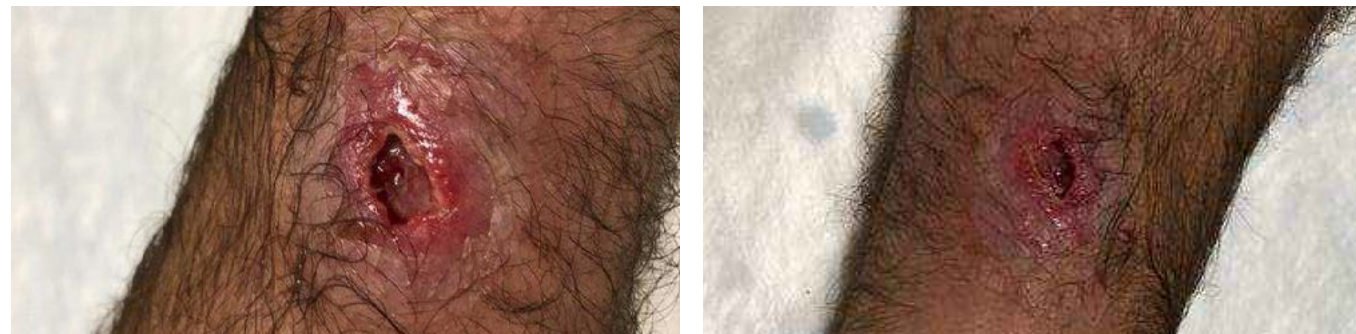DETAILS

Recommended diagnostics: Consider obtaining wound culture if this is recurrent. Resistance to traditional MRSA drugs is becoming more common.

Recommended actions: D/C telfa over packed wound - it is causing maceration of the wound because it has no absorptive capability. Cover wound with large fabric badaid instead. D/C order for "remove dressing at home and allow wound to dry out". Moist wound healing with adequate absorption of exudate is current standard of care. Moisture balance is essential to promote wound closure. D/C order for daily dressing change. Once infection is being treated (abx), goal is to identify dressing option that can be placed and will minimally disturb wound healing (as in daily remove and re-apply packing) and extend dressing change frequency. Wounds cool down every time they are exposed to "open to air"- wounds heal via body temperature, not room temperature. It takes 4-8 hours for wounds to warm to a temperature that promotes wound closure AFTER they have been exposed. I have provided readily available dressing options, as I do not know what you have available to you and your patients beyond gauze: New recommendations: 1) Cleanse wound with wound cleanser or saline 2) Apply small amount of bacitracin onto gauze packing strip and lightly tuck over wound 3) Cover with large fabric bandaid: Once wound has filled in, can D/C packing and apply small amount of bacitracin directly to the large fabric bandaid. 4) Please reinforce to Pt. the importance of thorough hand washing and use of disposable, non-sterile gloves. Dollar stores have boxes of 20 or 30 gloves for a few dollars (\$2-\$3) ... Please review "actions for Patient" prior to giving to patient to ensure the information is consistent with your local disposal laws.

Recommended patient actions: DRESSING CHANGES AT HOME: A PATIENT GUIDE DRESSING CHANGE FREQUENCY: Every other day and less frequently as wound closes. Removing the Old Dressing - Follow these steps to remove your dressing: • Wash your hands thoroughly with soap and warm water before and after each dressing change. • Put on a pair of non-sterile gloves (\$2 or \$3 at Dollar store). • Carefully remove any tape. • Remove the old dressing. If it is sticking to your skin, wet it with warm water to loosen it. • Remove the gauze pads or packing tape from inside your wound. • Put the old dressing, packing material, and your gloves in a plastic bag. Set the bag aside. Cleansing Your Wound - Follow these steps to cleanse your wound: • Put on a new pair of nonsterile gloves. • Cleanse your wound with either wound cleanser or saline, and pat dry with clean gauze. • Check the wound for increased redness, swelling, or a bad odor. • Pay attention to the color and amount of drainage from your wound. Look for drainage that has become darker or thicker. • After cleansing your wound, remove your gloves and put them in the plastic bag with the old dressing and gloves. • Wash your hands again. Changing Your Dressing - Follow these steps to put on a new dressing: • Put on a new pair of non-sterile gloves. • Apply bacitracin to packing strip and lightly tuck into and over wound base. • Cover with large fabric bandaid (You will be able to cover wound with fabric bandaid throughout closure - remove bandaid carefully to protect skin). Disposing of Soiled Dressing Material: • Place all used supplies in the plastic bag. Close it securely and place in the trash. • Wash your hands again when you are finished. • FOLLOW YOUR LOCAL LAWS REGARDING DISPOSAL OF SOILED DRESSINGS

Recommended follow up: DRESSING CHANGE FREQUENCY: Every other day and less frequently as wound closes. Once the wound demonstrates increased in growth of the healing red tissue, frequency of dressing changes can be decreased.



We add specialties to our panel frequently.

For the current list, please check aristamd.com

Example specialties include, but are not limited to:

Addiction Medicine

General

Allergy & Immunology

General

Pediatric

Cardiology

General

Heart Failure

Interventional Cardiology

Lipid Disorders

Pediatric

Dermatology

General

Dermatopathology

Pediatric

Endocrinology

General

Diabetes & Metabolism

Lipidology

Pediatric

ENT (Otolaryngology)

General

Head & Neck Cancer Surgery

Neurotology

Pediatric

Family Medicine/Internal Medicine

General

Gastroenterology

General

Hepatology

Inflammatory Bowel Disease (IBD)

Pediatric

Genetics

General

Geriatric Medicine

General

Palliative Care

Hematology/Oncology

General Hematology

General Oncology

Pediatric Hematology

Pediatric Oncology

Hospice & Palliative Medicine

General

Infectious Disease

General

HIV Medicine

Pediatric

Nephrology

General

Pediatric

Neurology

General

Pediatric

Epilepsy

Headaches

Neuromuscular Medicine

Neurosurgery

General

Obstetrics & Gynecology

General

Gynecology

General Obstetrics

Maternal-Fetal Medicine

Menopause/Perimenopause

Pediatric

Ophthalmology

General

Cataract

Pediatric

Retina

Orthopedic Surgery

General

Hand Surgery

Hip/Knee

Pediatric

Shoulder/Elbow

Sports Medicine

Pain Medicine

General

Psychiatry

General

Child & Adolescent

Psychology

General

Child & Adolescent

Pulmonology

General

Sleep Medicine

Pediatric

Radiology

General

Rheumatology

General

Pediatric

Surgery

General

Pediatric

Vascular Surgery

General

Transgender Medicine

General

Urology

General

Pediatric

Urogynecology

Weight Management

General

Eating Disorders

Obesity Medicine

